Clinical Article

J Minim Invasive Spine Surg Tech 2022;7(1):132-139
eISSN: 2508-2043
https://doi.org/10.21182/jmisst.2022.00437

JMISST
Journal of Minimally Invasive Spine Surgery and Technique

Multilevel Percutaneous Fenestrated Screw Fixation with Bone Cement Augmentation in Adult Lumbar Spinal Deformity

Soo Young Choi, Byung Rhae Yoo, Seong Son, Yong Ahn, Woo Kyung Kim, Sang Gu Lee

Department of Neurosurgery, Gachon University Gil Medical Center, Gachon University College of Medicine, Incheon, Korea

Received: February 10, 2022
Revised: March 17, 2022
Accepted: March 22, 2022

Corresponding Author:
Sang Gu Lee, MD, PhD
Department of Neurosurgery, Gachon University Gil Medical Center, Gachon University College of Medicine, 24 Namdong-daero 774beon-gil, Namdong-gu, Incheon 21565, Korea
Tel: +82-32-460-3304
Fax: +82-32-460-3899
E-mail: samddal@gilhospital.com

Objective: Fenestrated screw fixation with bone cement augmentation has been demonstrated to increase the pullout strength. Bone cement augmentation is performed to prevent screw failure. The study aimed to investigate the safety and efficacy of multilevel percutaneous fenestrated screw fixation with bone cement augmentation in the adult lumbar spinal deformity.
Methods: We performed a retrospective study of 15 patients who underwent multilevel percutaneous fenestrated screw fixation (PFSF) with bone cement augmentation between January 2018 and December 2020. Visual analogue scale (VAS) score, Oswestry disability index (ODI), sagittal vertical axis (SVA), and lumbar lordosis (LL) were investigated in the patients.
Results: Mean BMD was -2.0. The mean percutaneous fenestrated screw fixation level was 6. The mean VAS score changed from 7.14 preoperatively to 4.57 postoperatively, to 3.71 at the last follow-up. The mean ODI changed from 45.21 preoperatively to 32.5 postoperatively, to 27.0 at the last follow-up. The mean LL changed from 23.6 preoperatively to 32.96 postoperatively, to 31.67 at the last follow-up. The mean SVA changed from 76.65 preoperatively to 46.15 postoperatively, to 48.46 at the last follow-up. The bony fusion rate was 73.3%. There were screw loosening in 4 patients and screw fracture in 3 patients. Cement leakage occurred towards the anterior body of the vertebrae in 2 patients but no symptoms were observed.
Conclusion: Our study results demonstrate that multilevel PFSF with bone cement augmentation can result in good clinical and radiological outcomes for lumbar spinal deformity. However, larger size screws or smaller through-hole screws are required to prevent screw fracture.

Key Words: Pedicle screw, Osteoporosis, Bone cement, Spinal curvatures.

INTRODUCTION

As the aging population becomes more abundant, degenerative spine diseases are also increasing. With the development of surgical techniques for degenerative spinal diseases, various surgical methods have been introduced to obtain good surgical results. However, conventional surgical procedures for adult degenerative spinal deformity have been associated with severe blood loss, instrument failure, proximal junctional failure, and other complications found in elderly patients with multiple medical comorbidities.

Minimally invasive deformity correction and fusion remains as an exciting field of spinal deformity surgery. In adult lumbar spinal deformity, percutaneous fenestrated screw fixation

is a promising approach to spinal deformity surgery that can achieve correction and fusion with less tissue trauma, bleeding, and potentially fewer complications [1].

The biggest obstacle in performing spinal deformity surgery is osteoporosis [2]. As the number of osteoporotic patients increases, the related problems also increase. The anchoring effect of holding the screw in place is reduced and the probability of hardware failure becomes higher for osteoporotic patients. As a result, chances of non-union and complications such as screw loosening and pull-out also become higher.

Accordingly, various surgical fixation techniques have been introduced to address some of the problems encountered with osteoporotic patients. The use of larger and longer screws, addition of equipment such as hooks to increase screw fixation range, and injection of bone cement into the vertebral body around the screw have been some of the efforts made to overcome the weak bone integrity of osteoporotic patients. Among them, bone cement injection is mainly used to overcome osteoporosis. Bone cement augmentation is considered to be an effective method to increase the screw strength [3]. The challenge lies in the injection of bone cement while performing percutaneous pedicle screw fixation (PPF). Fenestrated screws were introduced to make the cement insertion process more convenient. A bone cement filler device is used to inject bone cement into the screw and the cement enters the vertebral body through small holes in the screw.

Injection of bone cement into percutaneous screws can inadvertently result in bone cement leakage at the screw head, which can make the rod fixation procedure difficult [4]. Screw fracture is another emerging complication for cement injecting screws, and the size of the screw hole through which the cement is injected seems like a very important factor in preventing screw fracture.

Although percutaneous transpedicular screw fixation alone may not be sufficient to correct spinal deformity, screw fixation with bone cement augmentation can reduce various complications such as loosening or pull-out screw that may commonly occur in conventional adult spinal deformity surgery [5]. This study aimed to investigate the safety and efficacy of multilevel percutaneous fenestrated screw fixation with bone cement augmentation in the adult lumbar spinal deformity.

MATERIALS AND METHODS

1. Patient Population

From January 2018 to December 2020, a total of 15 patients with lumbar spinal disease underwent multilevel PFSF with bone cement augmentation by a single experienced spine surgeon. There were 14 women and 1 man with a mean age of 71.3±7.2 years and a mean follow-up period of 19±7.5 months.

The following group of patients were included in this study.

1) Multilevel degenerative diseases such as spinal stenosis, spondylolisthesis with spinal deformity requiring PPF of at least 5 levels.
2) Spinal instability with spinal cord compression requiring PPF of at least 5 levels.
3) Osteopenic or osteoporotic patients who have poor bone quality.

Out of the 15 patients, 14 patients underwent surgery due to degenerative diseases, 1 patient due to burst fracture with instability. The mean BMD was –2.0±0.8. The Body Mass Index (BMI), past history (diabetes, hypertension, thyroid disease, renal failure and cardiac disease) were investigated in the patients (Table 1).

2. Surgical Method

The posterior lumbar interbody fusion (PLIF) and/or transforaminal lumbar interbody fusion (TLIF) with PPF via midline incision was performed in 10 patients, and direct lateral interbody fusion (DLIF) with percutaneous screw fixation in 5 patients. Multilevel PPF was performed in prone position using bone cement fenestrated screws (ZENIUS pedicle screw system distributed by Medyssey). The screws were placed percutaneously under fluoroscopic guidance. For every lumbar fenestrated screw, approximately 1.5–2.5 mL of polymethylmethacrylate (PMMA) was injected in the top and lower screws through the injection cannula. The rods were shaped according to the sagittal contour and then passed through the screw heads under fluoroscopic control. Compression or distraction was applied to the extenders as required to gain further correction.

3. Clinical and Radiologic Data

A retrospective review of clinical and radiological data was conducted. The visual analog scale (VAS) and the ODI scores were measured preoperatively, postoperatively (after 1 month of surgery) and at the last follow up. For radiological evaluation, SVA, PT, PI, SS, LL and Cobb's angle were measured through radiographs taken preoperatively, postoperatively (1–2 months after operation), and at last follow up (Figure 1).

The bony fusion rate of interbody fusion and instrument failure such as fracture or loosening were evaluated by radiographs

Table 1. Characteristics of patients

Case	Sex	Age	Diagnosis	Decompression levels	PPF levels	BMD	BMI	Past history
1	F	62	Scoliosis, stenosis and spondylolisthesis L2-5	TLIF L2-4, PLIF L45	5	−1.4	25.97	HTN, DM
2	F	76	Scoliosis, stenosis with instability L2-5	DLIF L2-5	7	−2.5	26.22	None
3	F	73	Scoliosis, stenosis with instability L3-S1	TLIF L3-5	5	−2.5	27.2	CRF
4	F	74	Stenosis and spondylolisthesis L2-S1	TLIF L2-S1	5	−0.7	26.3	HTN
5	F	80	Scoliosis, stenosis with instability L2-5	DLIF L2-5	5	−2.4	28.78	HTN
6	F	65	Scoliosis, stenosis with instability L2-S1	PLIF L2-5	6	−1.5	23.43	None
7	F	78	Scoliosis, stenosis with instability L3-S1	PLIF L34, TLIF L4-S1	5	−3.3	21.63	HTN
8	M	81	Scoliosis, stenosis with instability L1-5	TLIF L1-5	5	−1.5	23.31	None
9	F	62	Stenosis and spondylolisthesis L2-S1	DLIF L2-5, PLIF L5S1	6	−1.8	25.39	HTN
10	F	77	Stenosis and spondylolisthesis T12-S1	TLIF T12-S1	7	−2.1	24.03	HTN, DM
11	F	76	Scoliosis, stenosis with instability L1-5	TLIF L1-3, DLIF L3-5	6	−2.1	20.8	HTN, DM
12	F	72	Scoliosis, stenosis and spondylolisthesis L2-S1	TLIF L2-S1	5	−0.9	23.61	None
13	F	71	Stenosis and spondylolisthesis L1-S1	DLIF L1-4, PLIF L5S1	5	−1.9	19.29	HTN
14	F	73	Scoliosis, stenosis and spondylolisthesis L3-5	PLIF L3-5	8	−2.5	27.43	HTN
15	F	58	Old burst fracture L3, scoliosis	Corpectomy L3, DLIF L2-4	6	−3.2	20.9	None
Mean		71.3			6	−2.02	24.29	

PPF: percutaneous pedicle screw fixation, BMD: bone mineral density, BMI: body mass index, HTN: hypertension, DM: diabetes mellitus, CRF: chronic renal failure, DLIF: direct lateral interbody fusion, TLIF: transforaminal interbody fusion, PLIF: posterior lumbar interbody fusion.

and computed tomography (CT) during the follow-up period. The degree of bone fusion was based on the classification of Brantigan and Steffee (Table 2) [6]. Grade 4 or 5 was regarded to have achieved bony fusion. Screw loosening was defined as halo sign showing a radiolucent line of ≥1 mm around the screw in radiographs or CT [7].

Perioperative complications such as postoperative infection, PMMA and cerebrospinal fluid leakage, or neurologic deterioration were also recorded.

4. Statistical Analysis

For statistical analysis, ANOVA test was conducted using SPSS software (ver. 17.0; SPSS Inc, Chicago, IL, USA). A probability value of less than 0.05 was considered significant.

RESULTS

1. Clinical Outcomes

The mean VAS score decreased from 7.14 preoperatively to 4.57 postoperatively. VAS score decreased to 3.71 at the last follow up. The mean ODI score improved from 45.21 preoperatively to 32.5 postoperatively. Like the VAS score, ODI score improved to 27.0 at the last follow up. Both VAS and ODI score improved after the surgery and the improvement was maintained during the follow-up period with statistical significance ($p<0.05$).

2. Radiological Outcomes

Spinopelvic parameters were measured by three researchers (two experienced spine surgeons, one spine fellow), and the mean values were used for analysis.

The mean SVA decreased from 76.65 mm before the surgery to 46.15 postoperatively and 48.46 at the last follow-up. The mean LL increased from 23.60 before the surgery to 32.96 postoperatively however, decreased to 31.67 at the last follow-up. The mean PT decreased from 32.67 before the surgery to 28.11 postoperatively and 28.70 at the last follow-up. The mean PI-LL decreased from 35.20 before the surgery to 22.56 postoperatively and 22.76 at the last follow-up. The mean Cobbs angle decreased from 18.30 before the surgery to 6.27 postoperatively and 5.98 at the last follow-up (Table 3).

All the clinical and radiographic values were improved after the surgery and the improvement was well maintained during the follow-up period with statistical significance ($p<0.05$) (Figure 2). Figure 1 shows a 77-year-old patient that underwent PPF 6 levels with bone cement augmentation. SVA improves from 107.30 mm preoperative to 34.70 mm last follow-up, PT improves from 28.93 to 24.08, LL improves from 14.56 to 35.38, PI – LL improves from 38.13 to 14.22 and Cobb's angle improves from 28.69 to 4.12.

At the last follow-up, bony fusion was achieved in 11 patients

https://doi.org/10.21182/jmisst.2022.00437

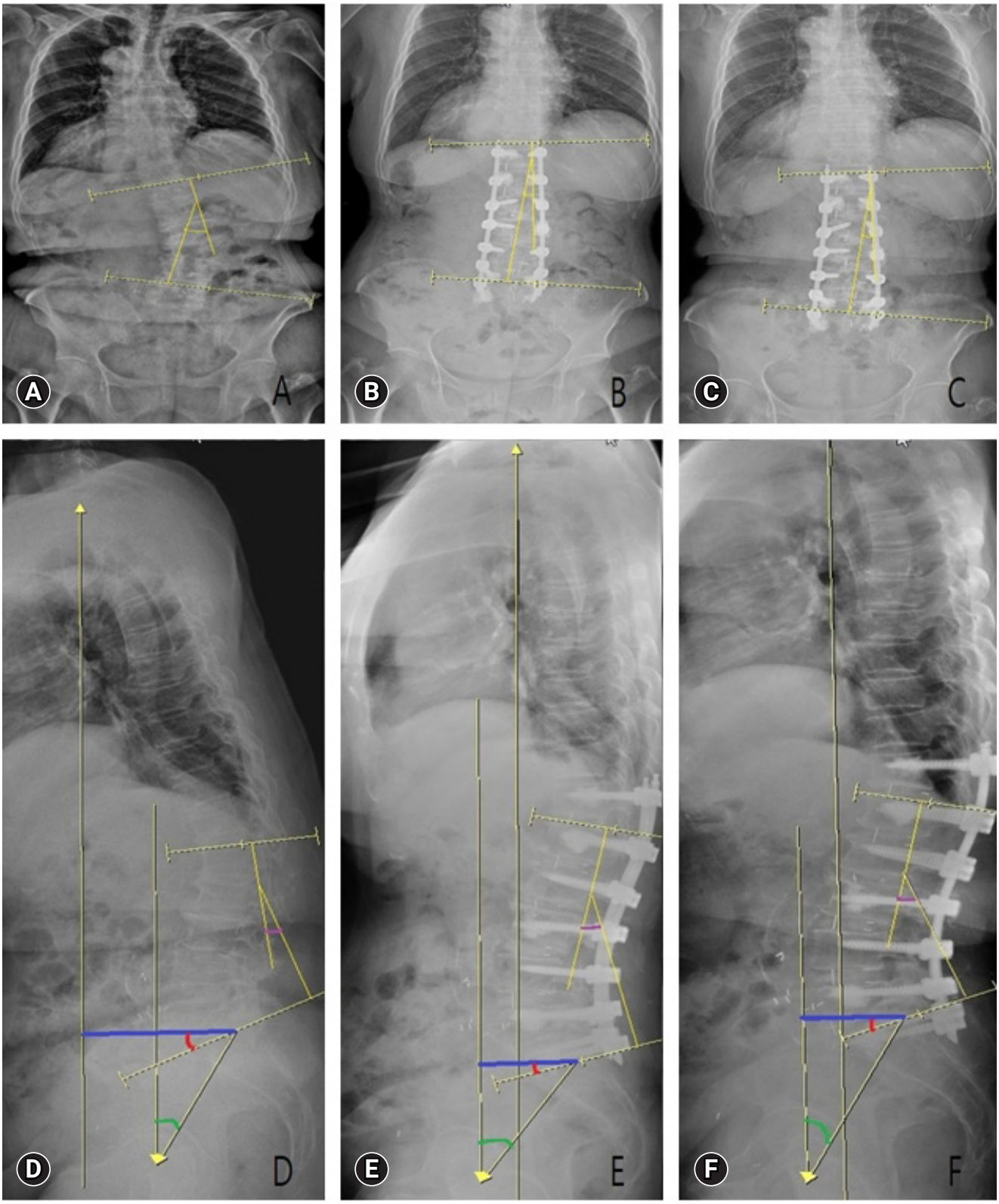

Figure 1. Female, 77-year-old, T=−2.1 SD, the patient underwent PPF with bone cement augmentation. (A) The preoperative A-P view X-ray image measured Cobb's angle; (B) Postoperative A-P view X-ray image measured Cobb's angle; (C) Last follow-up A-P view X-ray image measured Cobb's angle (yellow angle); (D) The preoperative lateral view X-ray image measured SVA (blue line), PT (green angle), SS (red angle), and LL (purple angle); (E) Postoperative lateral view X-ray image measured SVA, PT, SS, and LL; (F) Last follow-up lateral view X-ray image measured SVA, PT, SS, and LL.

Table 2. Discription of fusion result by Brantigan and Steffee [6]

Grade	Description
1	Obvious collapse of construct due to pseudoarthrosis, loss of disc height, vertebral slip, broken screws, displacement of the cage, resorption of bone graft
2	Probable significant resorption of the bone graft due to pseudoarthrosis, major lucency, or gap visible in fusion area (2 mm around the entire periphery of graft)
3	Uncertain non-union, bone graft visible in the fusion area ot approximately the density originally achieved at surgery. A small lucency of gap may be visible involving a portion of the fusion area with at least half of the graft area.
4	Probable fusion bone bridges entire fusion area with at least the density achieved at surgery. There should be no lucency between the donor and vertebral bone.
5	Fusion bone in the fusion area is radiographically more dense and mature than originally achieved by surgery. Optimally, there is no interface between the donor bone and the vertebral bone, although a sclerotic line between the fusion areas, resorption of the anterior traction spur, anterior progression of the graft within disc space, and fusion of facet joints.

Table 3. Radiological outcomes of patients

Index	Preoperative	Postoperative	Last follow-up	p-value
PT	32.67	28.11	28.70	0.003
LL	23.60	32.96	31.67	0.011
PI-LL	35.20	22.56	22.76	0.001
Cobb's angle	18.30	6.27	5.98	0.002
SVA (mm)	76.65	46.15	48.46	0.009

PT: pelvic tilt, LL: lumbar lordosis, PI-LL: pelvic incidence minus lumbar lordosis, SVA: sagittal vertical axis.

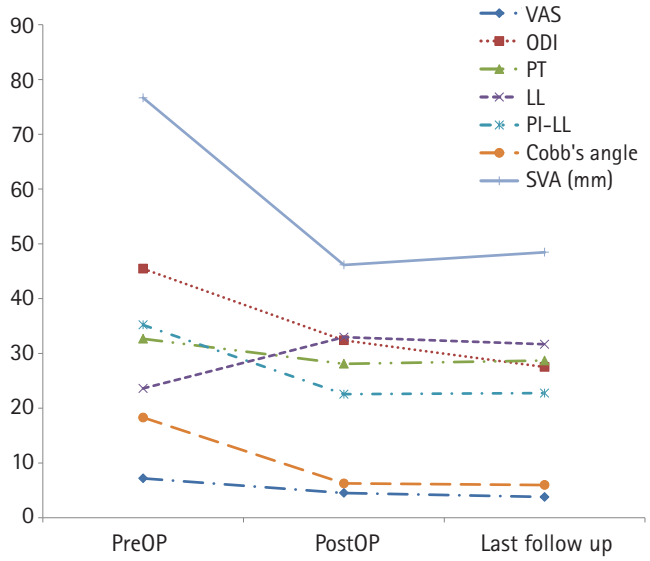

Figure 2. Graph showing Visual Analog Scale (VAS), Oswestry Disaability Index (ODI), Pelvic Tilt (PT), Lumbar Lordosis (LL), Pelvic incidence minus Lumbar Lordosis (PI-LL), Cobb's angle, and Sagittal Vertical Axis (SVA) before the surgery, 1–2 months after the surgery (postoperative period), and last follow-up period. The mean improvement of VAS from pre-operation to the last follow-up was 3.43 points (from 7.14 to 3.71) ($p<0.05$). The mean improvement of ODI from the pre-operation to the last follow-up was 18.21 points (from 45.21 to 27.0) ($p<0.05$). All the last follow-up radiologic outcomes improves than before the surgery ($p<0.05$). X axis represents preoperative, postoperative, and last follow-up period. The Y axis represents the score.

out of 15 patients and thus the fusion rate was 73.3%. Screw loosening was observed in 4 patients, rod fracture in 1 patient and screw fracture in 3 patients. Among the 3 patients of screw fracture, 1 patient underwent screw pull-out at the top screw and required reoperation. Cement leakaged occurred in 2 patients through the anterior body of vertebrae but no symptoms were observed. There were no cases of postoperative surgical site infection (Table 4).

DISCUSSION

Multilevel PFSF in adult spinal deformity is becoming a popular option among surgeons for the aging population. PPF decreases muscle crush injures during retraction, avoids detachment of tendons to the posterior bony elements, maintains the integrity of the dorsolumbar fascia, limits bony resection, and decreases the size of the surgical corridor. But technical limits of PPF also exists. Facet hypertrophy, high iliac crest when screwing S1 segment, severe spondylolisthesis, osteopenia or osteoporosis, and scoliosis [8].

Therefore, perioperative complications such as screw loosening or fracture are commonly encountered. Studies have demonstrated that 17% of revision surgeries are associated with fenestrated screw failure [4,9]. Longer, thicker sized screws, bone cement augmentation along with teriparatide injections have been applied to overcome such instrument failure. This study was aimed to evaluate safety and efficacy of percutaneous fenestrated screw with bone cement augmentation in adult lumbosacral degenerative spine diseases with low bone quality.

There are two main methods of screw augmentation currently in practice. One method is using a fenestrated screw, through which bone cement is injected via injection cannula after screw insertion. The other conventional augmentation method involves tapping over the guidewire, bone cement injection through a injection cannula, followed by screw insertion. A pre-

https://doi.org/10.21182/jmisst.2022.00437

Table 4. Complications related to procedure

	Number
Screw fracture	3
Screw loosening	4
Screw pull-out	1
Rod fracture	1
Leakage of cement	2
Postoperative surgical site infection	0

vious study demonstrated that fenestrated screw augmentation is more effective than vertebroplasty augmentation [5].

Many problems can occur during the bone cement augmentation process. Cement leakage into the spinal canal or intervertebral foramen causing neural obstructions and neurologic damage to the nearby nerve root as a result of the chemical reaction of the PMMA are some of the common complications [10,11]. More serious complications such as pulmonary embolism, paraplegia, or death can also occur [12]. In our patients at least 1.5 mL of bone cement was injected at each fenestrated screw based on the study that 1.5 mL is an effectiveness dose that increases the pullout strength and minimizes the risks associated with higher volume [13].

In this study, all sagittal parameters improved post-operatively compared to the pre-operative state. The correction rate of the sagittal imbalances was not ideal according to SRS-Schwab Classification, but all patients showed clinical improvements postoperatively and at the last follow up. Sagittal corrections needed to be tailored to each patient characteristic based on bone quality and patient comorbities. Increased post-surgical infection and dural tear, massive blood loss during surgery, proximal junctional kyphosis, and rod fracture or haloing around screw can occur when excessive correction is performed [14].

In this study bony fusion rate was 73.3%, which is somewhat lower than the previously reported 93.47% [4]. This may be due to the fact that ideal sagittal correction values could not be achieved based on the limitations of the PPF technique, which in turn leads to spinal instability and unbalanced load baring on the screws and rods. Screw fractures occurred in three patients. In all of the screw fracture cases, large holed screws were used. While large holed screws allow much easier cement injection, screw integrity may be compromised and the chances of inadvertent cement leakage become more abundant. Consistent with previous study of cement leakage rate of 9.3%, cement leakage occurred in two of fifteen patients (13.3%) [5]. Cement leakage occurred through the anterior body of vertebrae but no symptoms were triggered. Bone cement injection can also occur at the screw head to which the injection cannula is attached. Such leakage can make the rod fixation procedure difficult and operation time longer. Removal of excess bone cement at the screw heads is a crucial process before rod application to ensure appropriate capping. Screw pull-out occurred in one patient at the uppermost screw fixation level (L2). Female, 73-year-old, T=–2.5 SD, the patient has history of chronic renal failure (CRF) that operation of TLIF L3-5 PPF L2,3,4,5,S1. But screw pull-out occurred at the L2 level that removal of instrument L2-S1 bilateral and allobone chips was applied at the reoperation surgery (Figure 3). Screw loosening occurred in four cases. Screw loosening occurred due to insufficient bone cement injection on the loosening site in one patient, but all screw loosening cases did not result in spinal instability. In this study, the mean BMD was –2.02. The mean BMD of the screw loosening group was –2.87, and the mean BMD of the those without instrument failure was –1.73. Mean BMD values of screw loosening cases was significantly lower than those of without instrument failure. The rate of instrument related complications was quite high compared to other studies about multilevel fusion. We believe that the use of large holed fenestrated screws and lengthy fusion levels (mean fusion level of 6) can be attributed to these results. Previous studies have shown that age, more than 5 fusion levels, scoliosis, PI/LL mismatch and osteoporosis to be associated with high risk of instrument failure [15].

In light of the results, it is important to improve the bone quality to decrease the rate of instrument failure. Using teriparatide injection after the surgery has proven to be an effective adjunctive treatment [16]. In this study a daily injection of 20 μg of teriparatide for 6 months was prescribed to all osteoporosis patients. But based on our experience, teriparatide injections should be recommended to osteopenia patients when multilevel fusion is being considered in order to reduce screw loosening.

There are many limitations to the study. Selection bias may have occurred due to the retrospective nature of the study. The sample size is also very small and the follow-up period is not long enough to discuss long term outcomes. This study does not have a control group to which we can compare the results of using fenestrated cement screws. Thus, a randomized control study with more patients and longer follow-up duration is needed to reinforce our results. This study is significant in that PPF with bone cement augmentation can conveniently and safely be performed using fenestrated screws in adult deformity surgery.

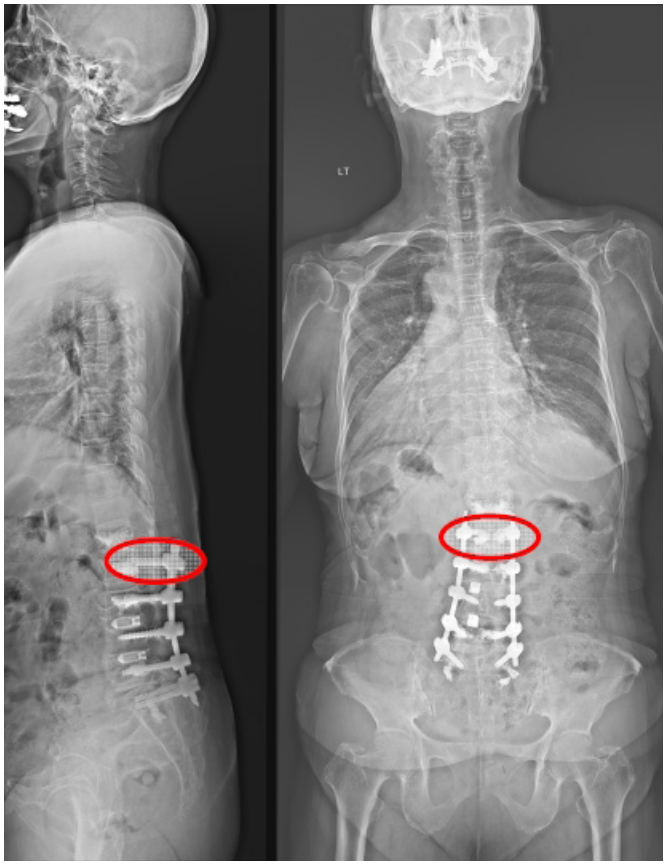

Figure 3. Female, 73-year-old, T=−2.5 SD, the patient has history of CRF that operation of TLIF L3-5 PPF L2, 3, 4, 5, S1. Screw pull-out occurred at the uppermost screw fixation level (L2).

CONCLUSION

Although the current study examined a small sample with a relatively short term follow up period, our study results demonstrate that multilevel percutaneous fenestrated screw fixation with bone cement augmentation can result in good clinical and radiological outcomes for lumbar spinal deformity. Based on our experience, we believe that bone cement augmentation should be performed at all levels for severely osteoporotic patients and at least at the uppermost and lowermost level in osteopenia patients or those undergoing more than four level fusion to minimize instrument failure. Large holed screws used for bone cement augmentation may be vulnerable to screw fracture and increase the risk of screw fracture. Larger size screws or smaller through-holed screws are necessary to prevent screw fracture. Teriparatide injection for at least 6 months is recommended after percutaneous screw fixation in low bone quality patients.

CONFLICT OF INTEREST

No potential conflict of interest relevant to this article.

REFERENCES

1. Son S, Lee SG, Park CW, Kim WK. Minimally invasive multilevel percutaneous pedicle screw fixation for lumbar spinal diseases. Korean J Spine 2012;9:352–357.
2. Gupta A, Cha T, Schwab J, Fogel H, Tobert DG, Razi AE, et al. Osteoporosis is under recognized and undertreated in adult spinal deformity patients. J Spine Surg 2021;7:1–7.
3. Seo JH, Ju CI, Kim SW, Kim JK, Shin H. Clinical efficacy of bone cement augmented screw fixation for the severe osteoporotic spine. Korean J Spine 2012;9:79–84.
4. Tang YC, Guo HZ, Guo DQ, Luo PJ, Li YX, Mo GY, et al. Effect and potential risks of using multilevel cement-augmented pedicle screw fixation in osteoporotic spine with lumbar degenerative disease. BMC Musculoskelet Disord 2020;21:274.
5. Kim JH, Ahn DK, Shin WS, Kim MJ, Lee HY, Go YR. Clinical effects and complications of pedicle screw augmentation with bone cement: comparison of fenestrated screw augmentation and vertebroplasty augmentation. Clin Orthop Surg 2020;12:194–199.
6. Brantigan JW, Steffee AD. A carbon fiber implant to aid interbody lumbar fusion. Two-year clinical results in the first 26 patients. Spine (Phila Pa 1976) 1993;18:2106–2107.
7. Moon BJ, Cho BY, Choi EY, Zhang HY. Polymethylmethacrylate-augmented screw fixation for stabilization of the osteoporotic spine : a three-year follow-up of 37 patients. J Korean Neurosurg Soc 2009;46:305–311.
8. Yuan L, Zhang X, Zeng Y, Chen Z, Li W. Incidence, risk, and outcome of pedicle screw loosening in degenerative lumbar scoliosis patients undergoing long-segment fusion. Global Spine J 2021 doi: 10.1177/21925682211017477
9. Bostelmann R, Keiler A, Steiger HJ, Scholz A, Cornelius JF, Schmoelz W. Effect of augmentation techniques on the failure of pedicle screws under cranio-caudal cyclic loading. Eur Spine J 2017;26:181–188.
10. Sawakami K, Yamazaki A, Ishikawa S, Ito T, Watanabe K, Endo N. Polymethylmethacrylate augmentation of pedicle screws increases the initial fixation in osteoporotic spine patients. J Spinal Disord Tech 2012;25:E28–E35.
11. Fan HT, Zhang RJ, Shen CL, Dong FL, Li Y, Song PW, et al. The biomechanical properties of pedicle screw fixation combined with trajectory bone cement augmentation in osteoporotic vertebrae. Clin Spine Surg 2016;29:78–85.

https://doi.org/10.21182/jmisst.2022.00437

12. Lee BJ, Lee SR, Yoo TY. Paraplegia as a complication of percutaneous vertebroplasty with polymethylmethacrylate: a case report. Spine (Phila Pa 1976) 2002;27:E419–E422.
13. Paré PE, Chappuis JL, Rampersaud R, Agarwala AO, Perra JH, Erkan S, et al. Biomechanical evaluation of a novel fenestrated pedicle screw augmented with bone cement in osteoporotic spines. Spine (Phila Pa 1976) 2011;36:E1210–E1214.
14. Hyun SJ, Rhim SC. Clinical outcomes and complications after pedicle subtraction osteotomy for fixed sagittal imbalance patients : a long-term follow-up data. J Korean Neurosurg Soc 2010;47:95–101.
15. Marie-Hardy L, Pascal-Moussellard H, Barnaba A, Bonaccorsi R, Scemama C. Screw loosening in posterior spine fusion: prevalence and risk factors. Global Spine J 2020;10:598–602.
16. Kim JW, Park SW, Kim YB, Ko MJ. The effect of postoperative use of teriparatide reducing screw loosening in osteoporotic patients. J Korean Neurosurg Soc 2018;61:494–502.